Rtg. bekken front av traumepasient
Fremdeles nyttig?

Johan C Hellund
Avd for radiologi og nukleærmedisin, Ullevål
Oslo Universitetssykehus

Svaret:

Ja !

Hvorfor ja?

- Traume triage
  - A
  - B
  - C

Hvorfor ja?

- Traume triage
  - Airways
  - Breathing
  - Circulation

Hvorfor ja?

- Traume triage
  - Airways
  - Breathing
  - Circulation
- Sagt radiologisk:
- Rtg thorax front

Hvorfor ja?

- Traume triage
  - Airways
  - Breathing
  - Circulation
- Sagt radiologisk:
- Rtg thorax front
- Rtg bekken front

Hvorfor ja?

- Traume triage
  - Airways
  - Breathing
  - Circulation
- Sagt radiologisk:
- Rtg thorax front
- Rtg bekken front
  - Tegn på fraktur / avrevne ligamenter?
    - indikasjoner på mulig blødning

Blødning pga:

- **Bekkenring skade**
- Acetabular fraktur
- Andre frakturer

Fokus på !!

- Krefter som virker på bekkenet – type traume
- Normal funn- “checkpoints”
- “What you don’t see”

Krefter som virker på bekkenringen

- Anteriorposterior kompresjon
- Lateral kompresjon
- Vertikal skjæring
- Kombinasjon av disse 3

- (Krefter som virker på acetabulum)

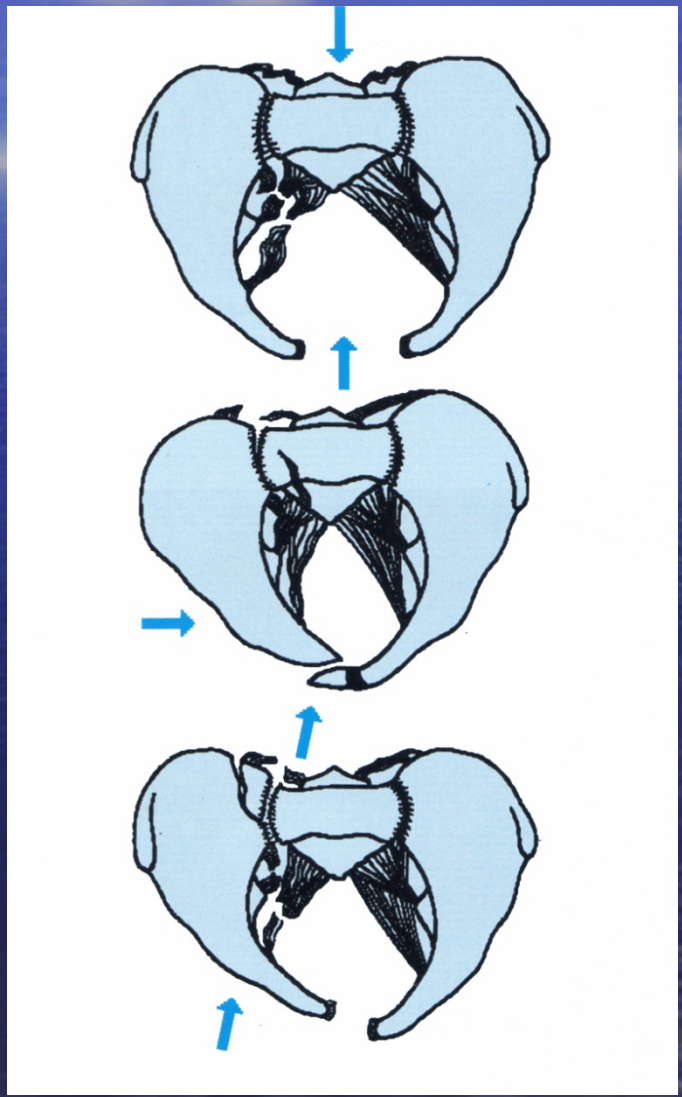

NEVER EVER GIVE UP

Checkpoints

- 3 benede ringer
  - Inngang lille bekken (Linea terminalis)
  - Foramen obturatorium

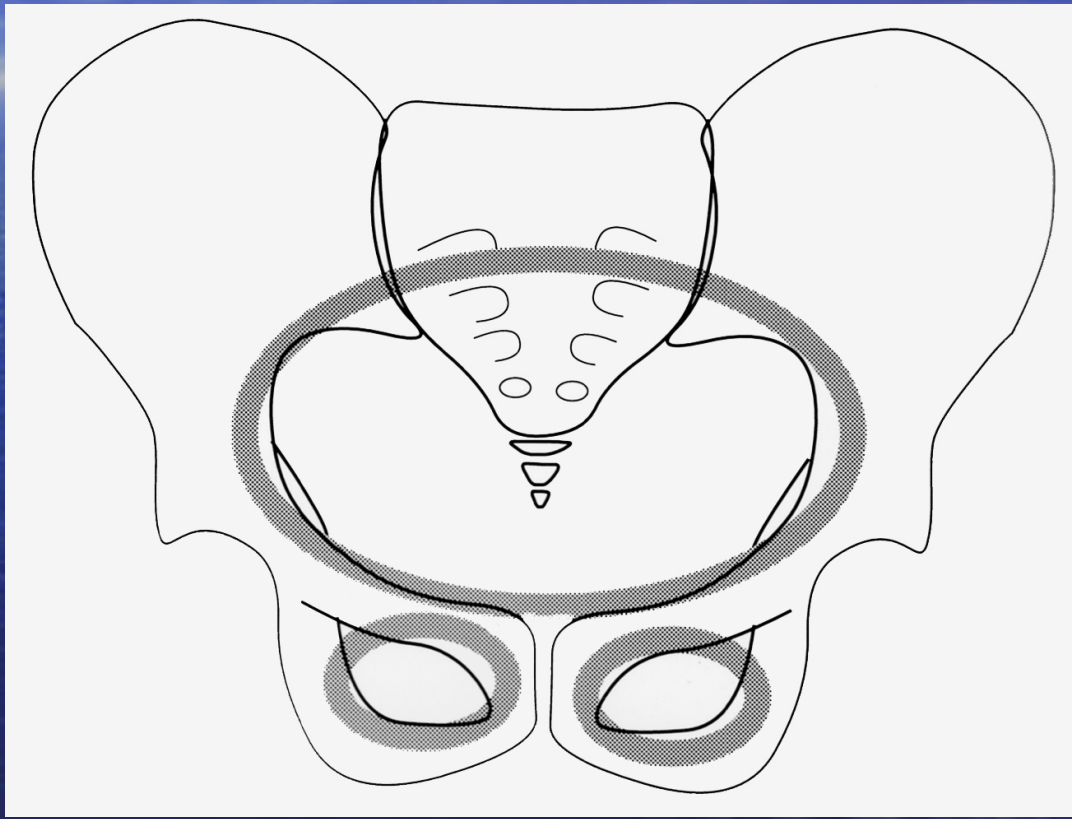

Brutte benede ringer?

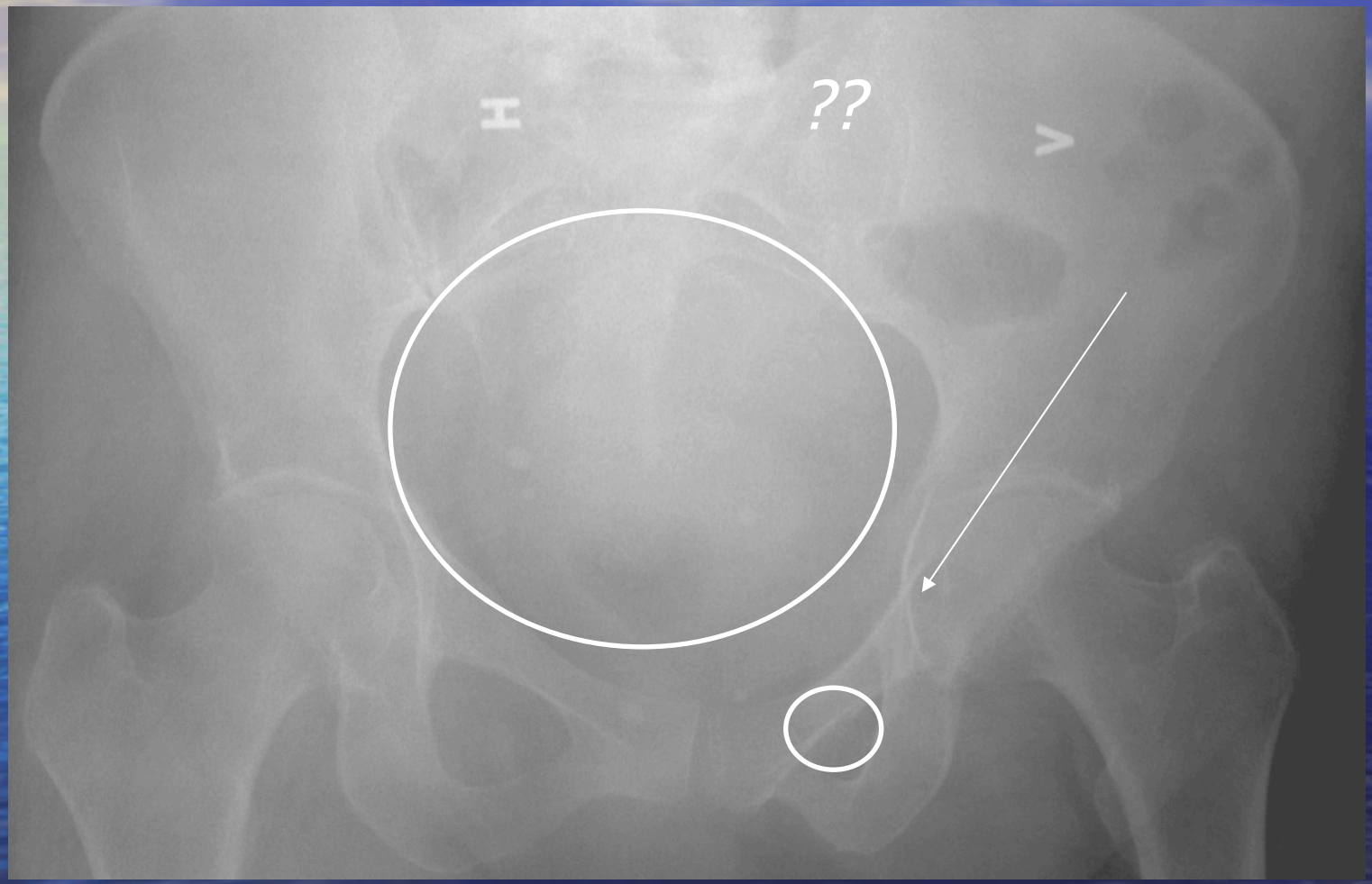

Fraktur et sted i benringen er assosiert med fraktur annet sted!!

Checkpoints

- "Alignment" i
  - IS-ledd
  - Symfysen
  - Linea arcuata

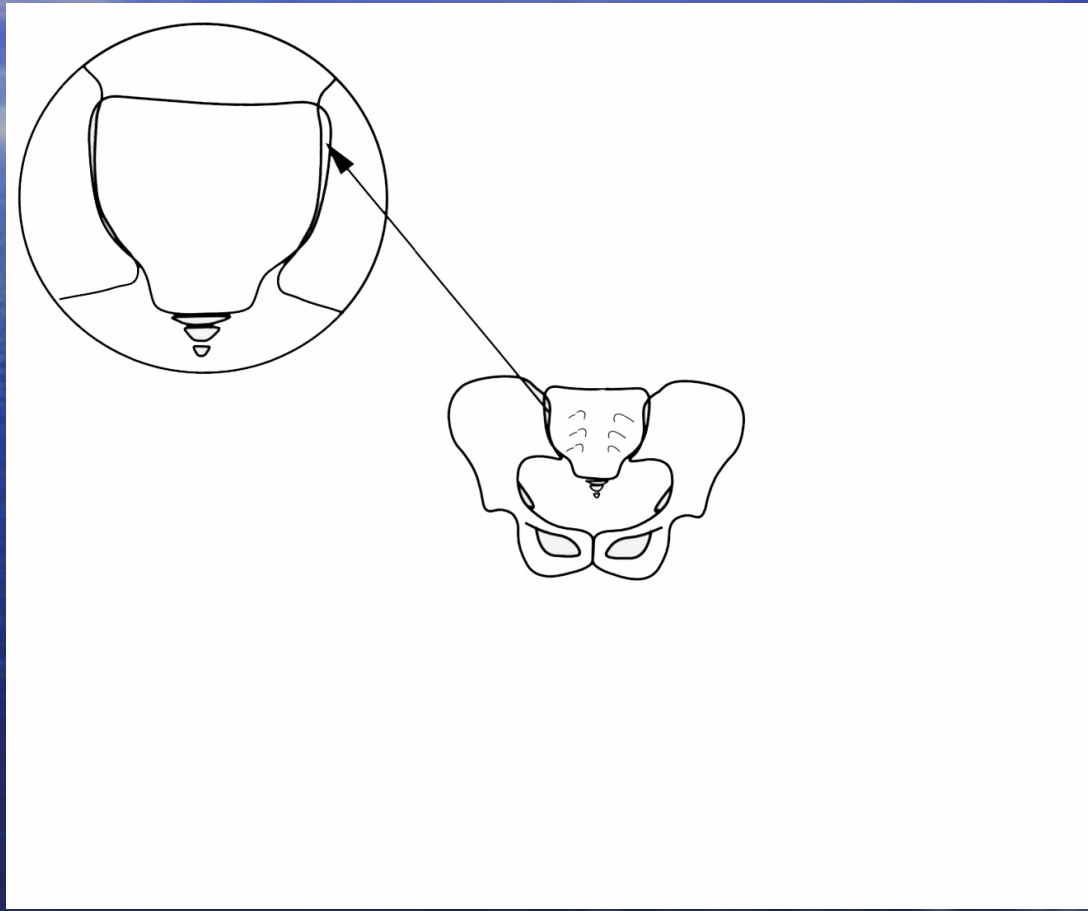

AP kraft– ”Åpen bok”

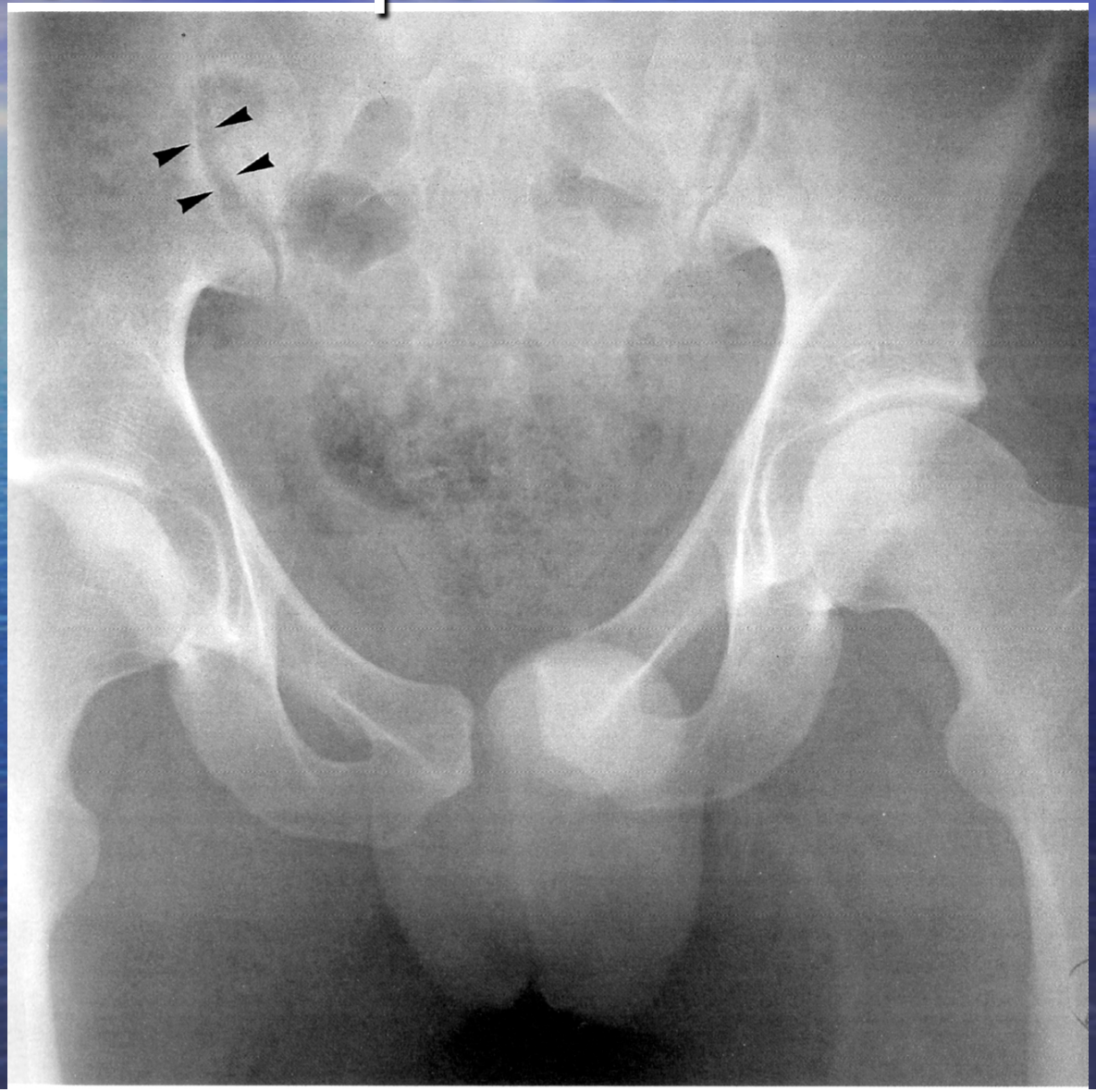

Checkpoints

- "Alignment" i
  - IS-ledd
  - Symfysen
  - Linea arcuata

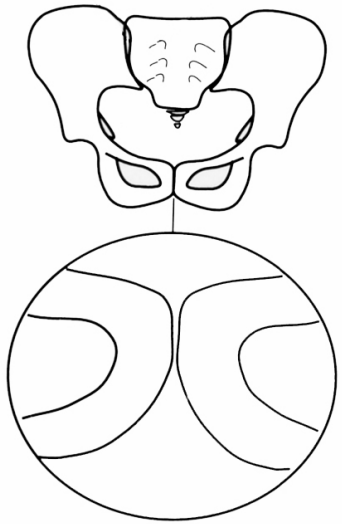

Økt avstand i symfysen

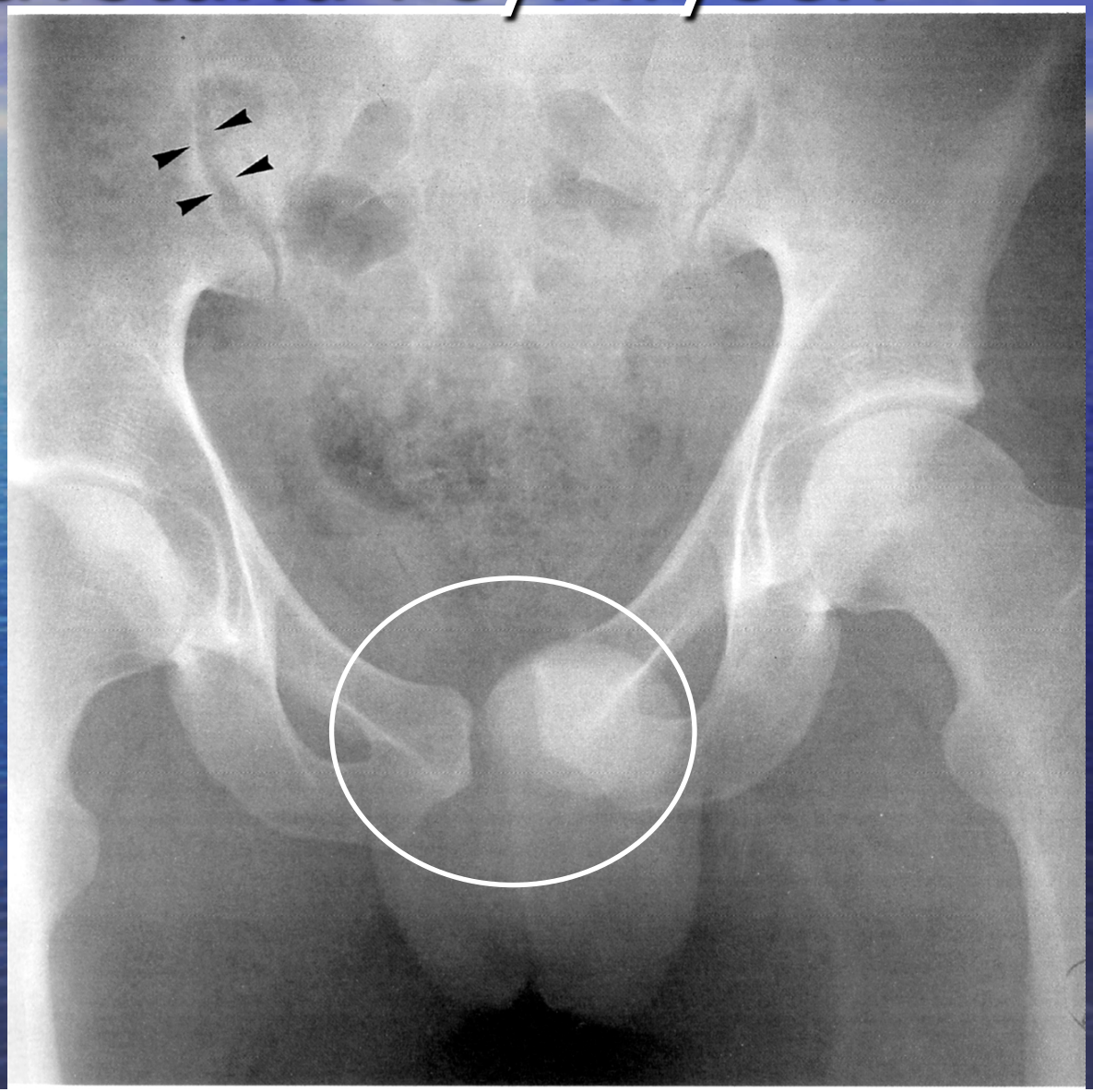

Checkpoints

- "Alignment" i
  - IS-ledd
  - Symfysen
  - Linea arcuata

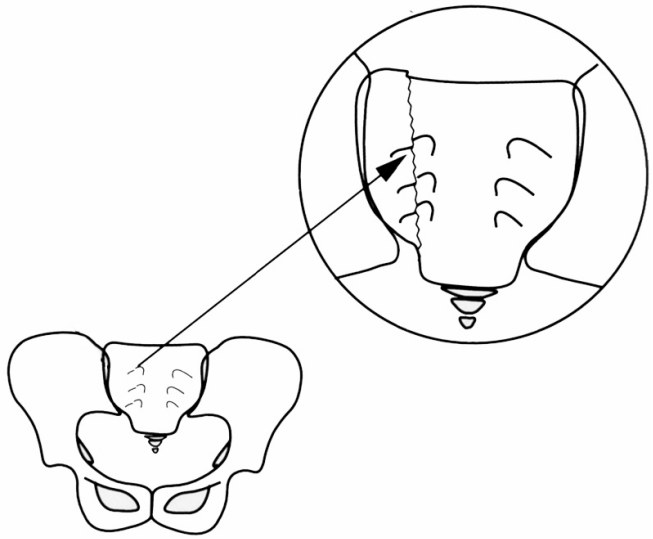

Fraktur i linea arcuata

Checkpoints

- **Alignment !!**

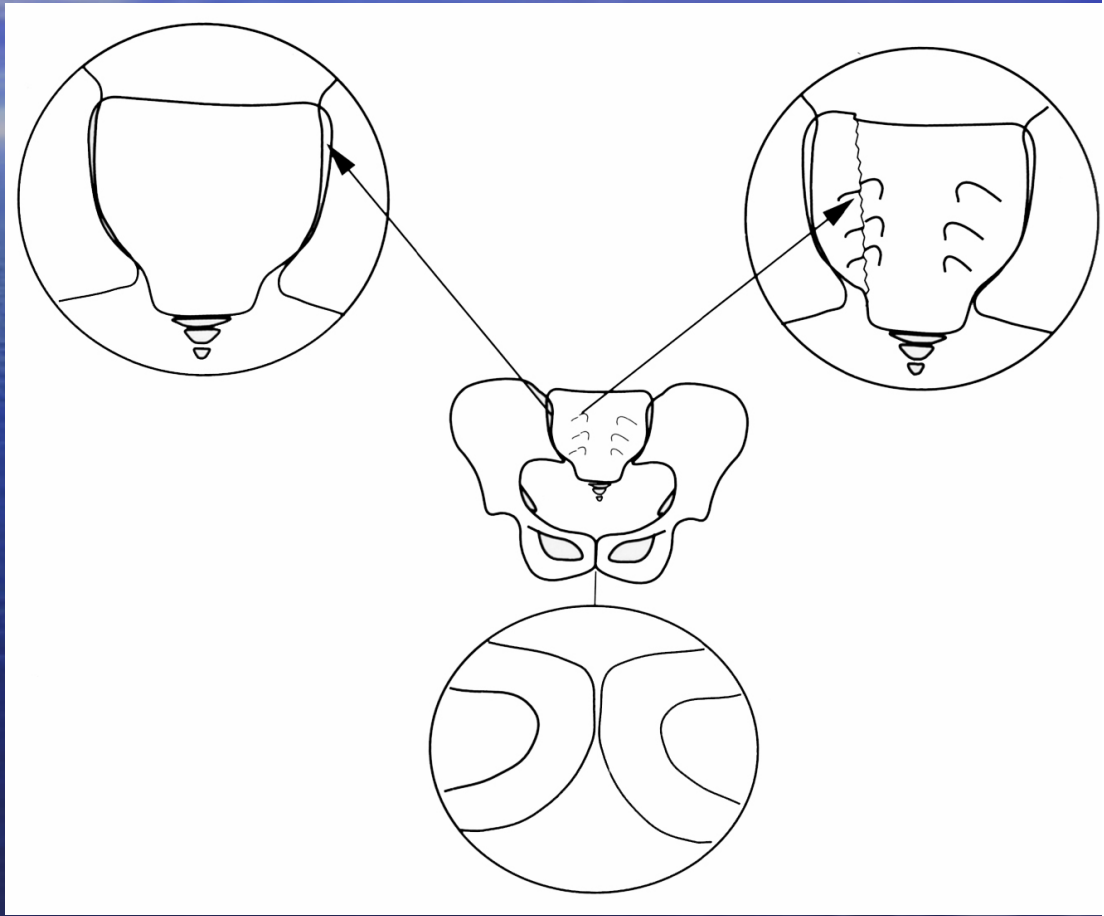

Checkpoints

- Acetabulum
  - Bakre og fremre vegg
  - Tåredråpen
- L5
- Hofte fraktur
  - Shenton's linje

Checkpoints

- Acetabulum
  - Bakre og fremre vegg
  - Tåredråpen
- L5
- Hofte fraktur
  - Shenton's linje

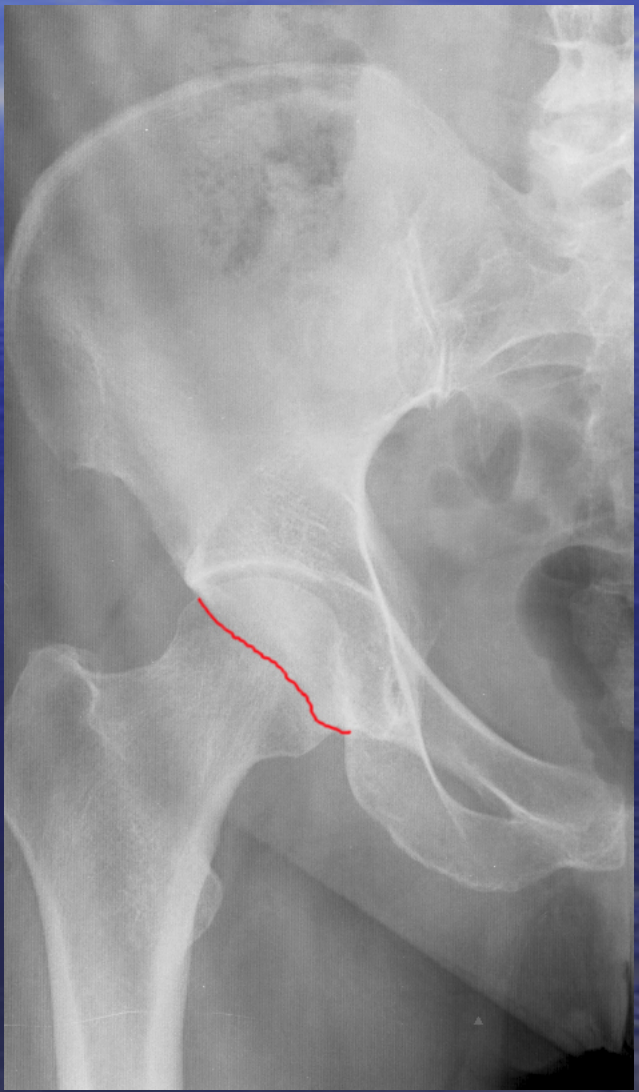

Checkpoints

- Acetabulum
  - Bakre og fremre vegg
  - Tåredråpen
- L5
- Hofte fraktur
  - Shenton's linje

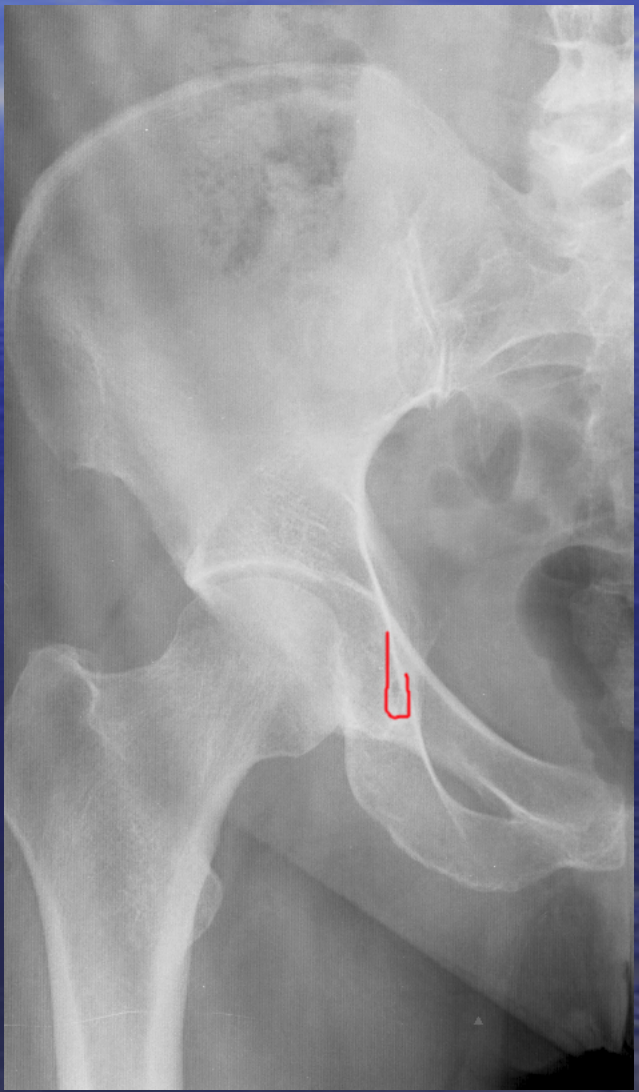

Checkpoints

- Acetabulum
  - Bakre og fremre vegg
  - Tåredråpen
- L5
- Hofte fraktur
  - Shenton's linje

Checkpoints

- Acetabulum
  - Bakre og fremre vegg
  - Tåredråpen
- L5
- Hofte fraktur
  - Shenton's linje
    - Brutt foramen obturatorium?

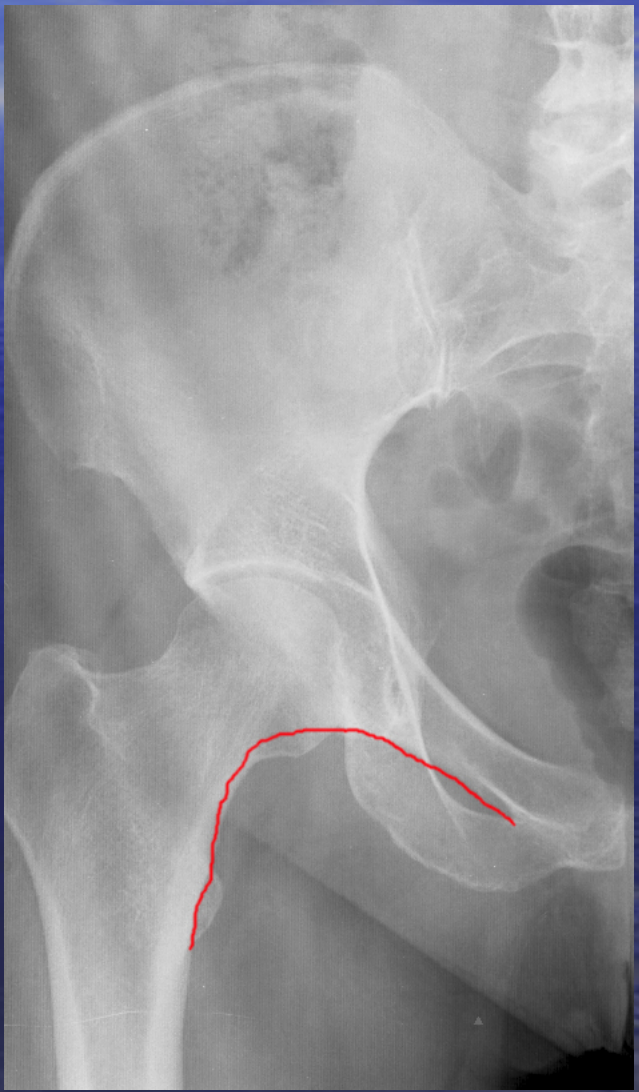

Acetabulum – Bakre vegg

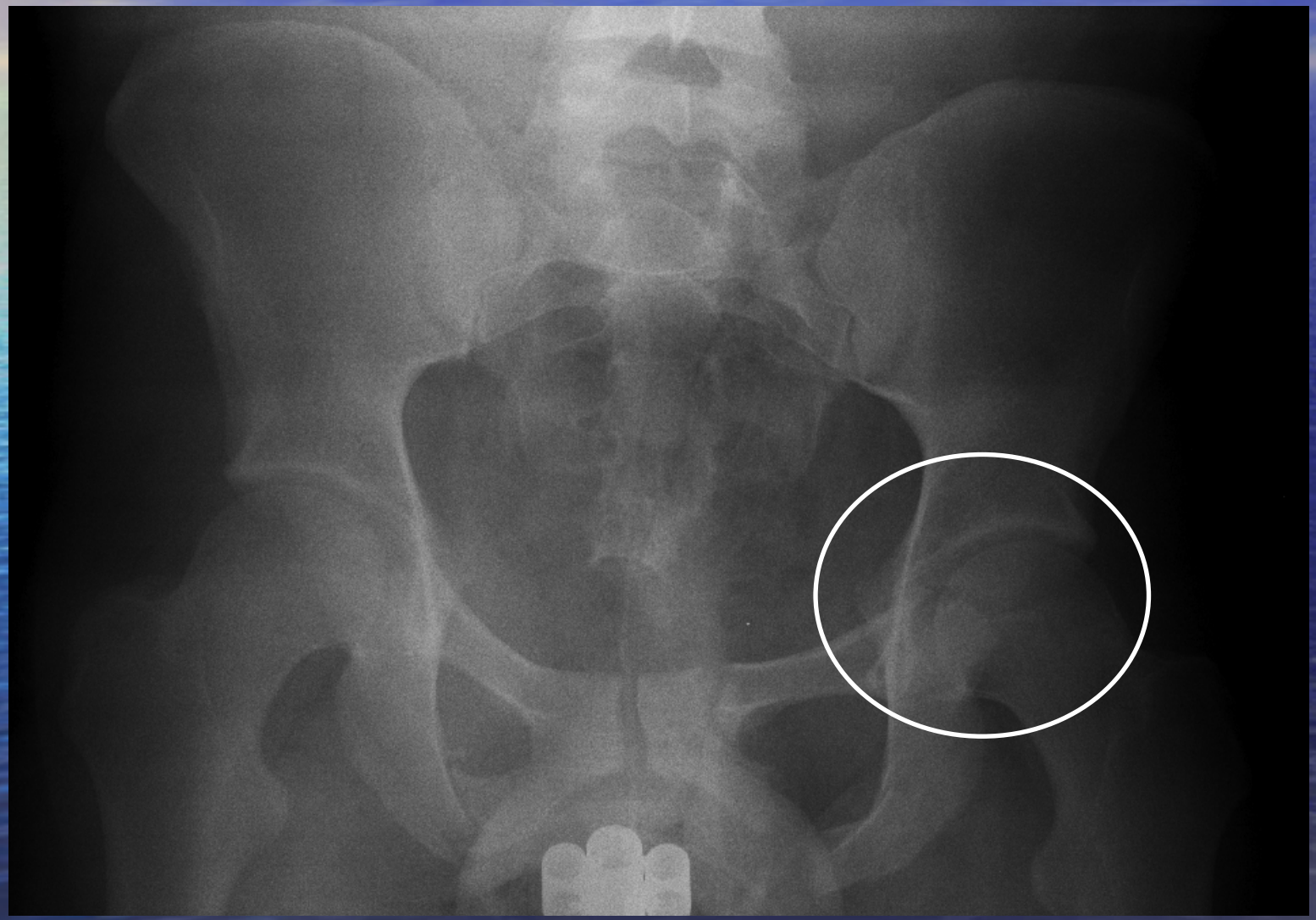

Acetabulum + ring + sacrum

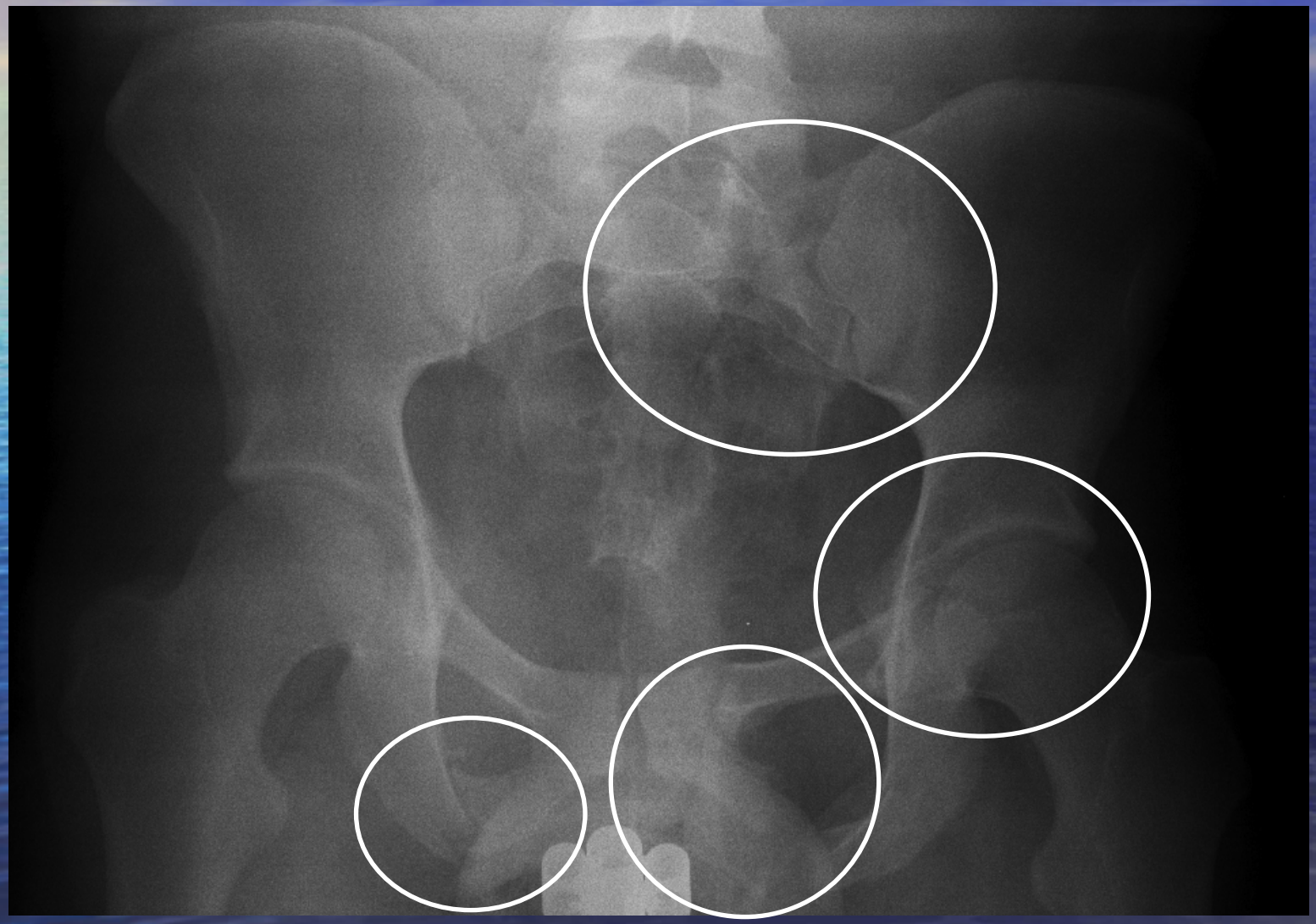

L5 fx og brutt ring (+ femur fx)

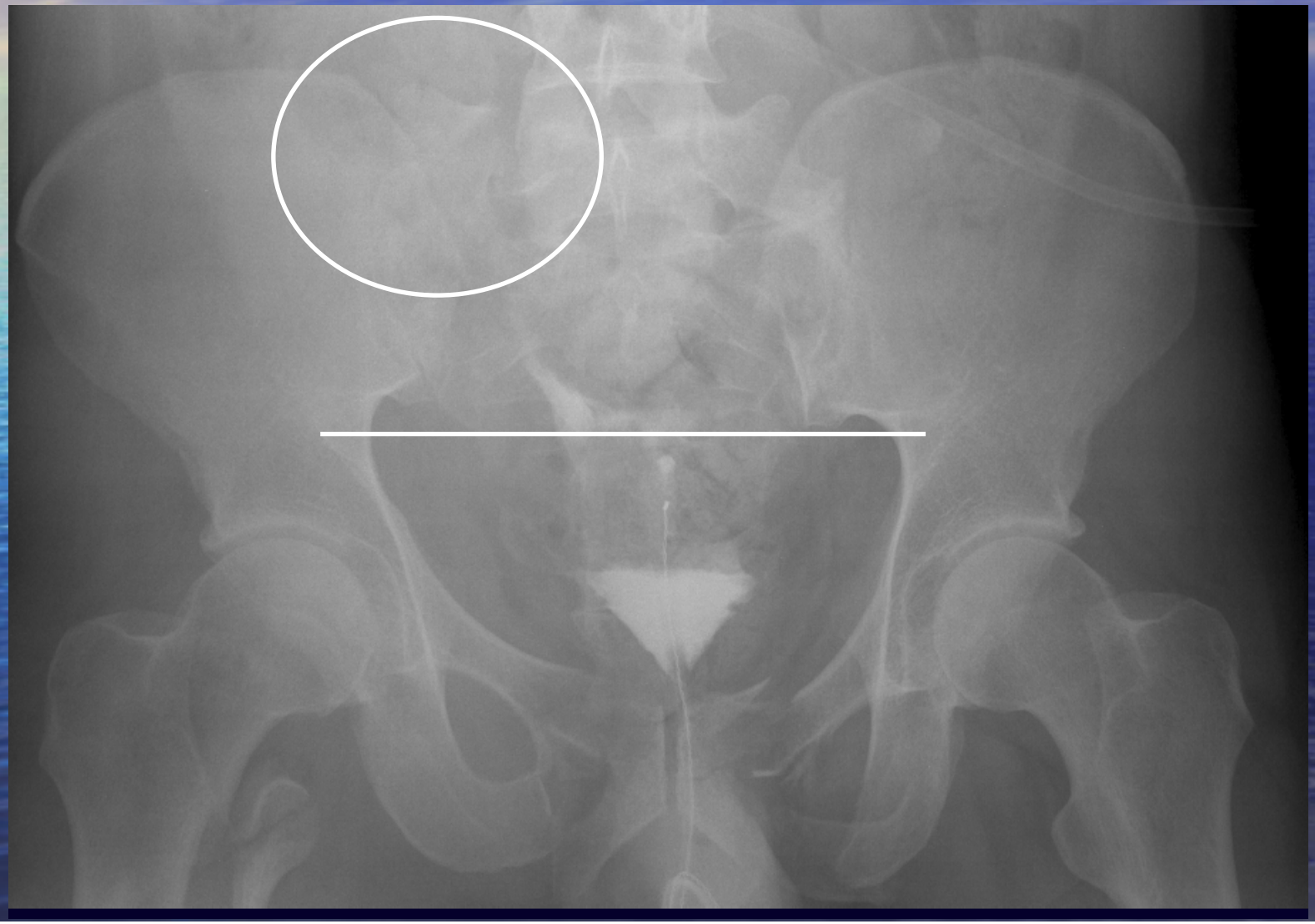

Vertikal skjærings skade

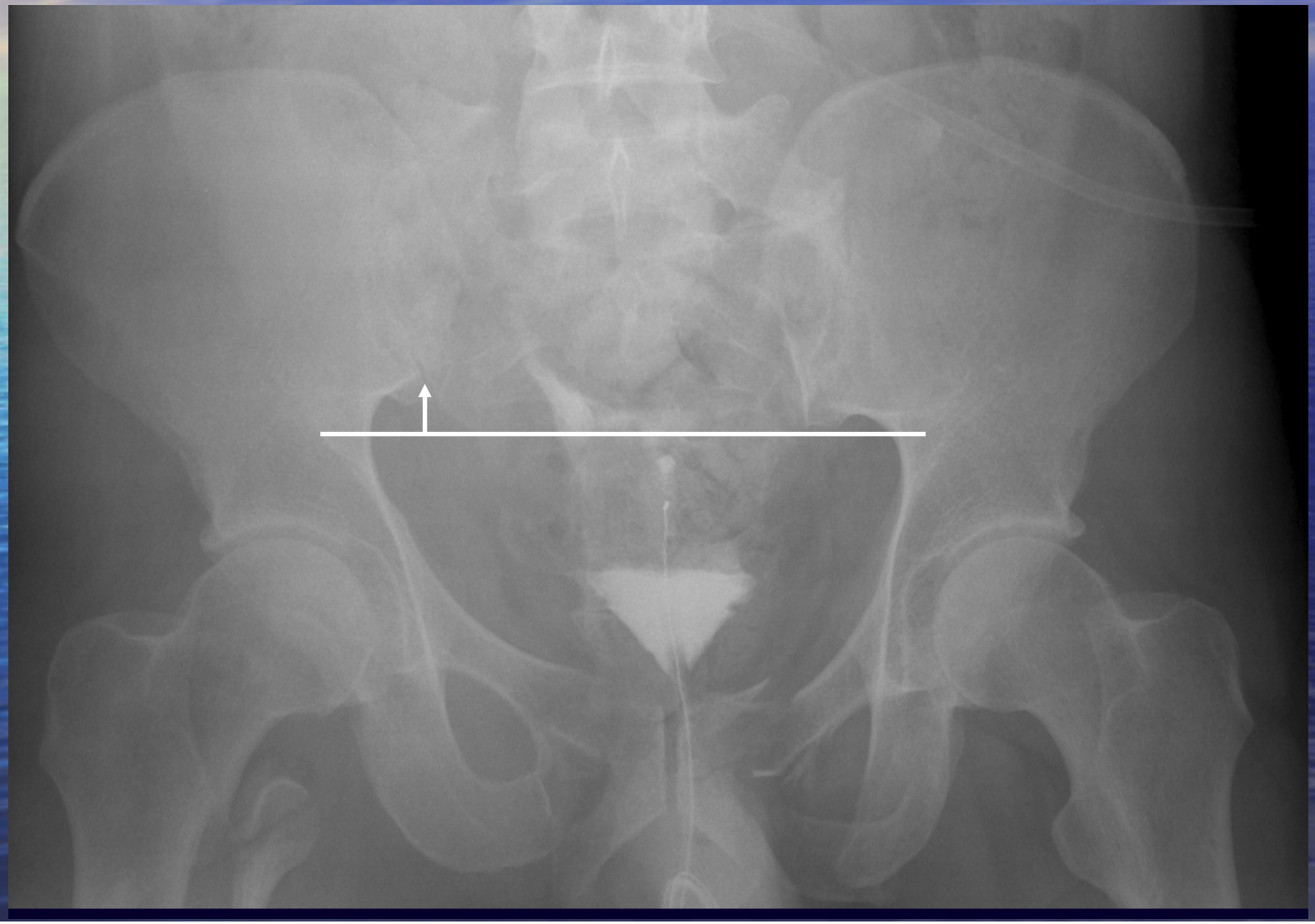

Brutt Shenton's linje

Luksert hofte

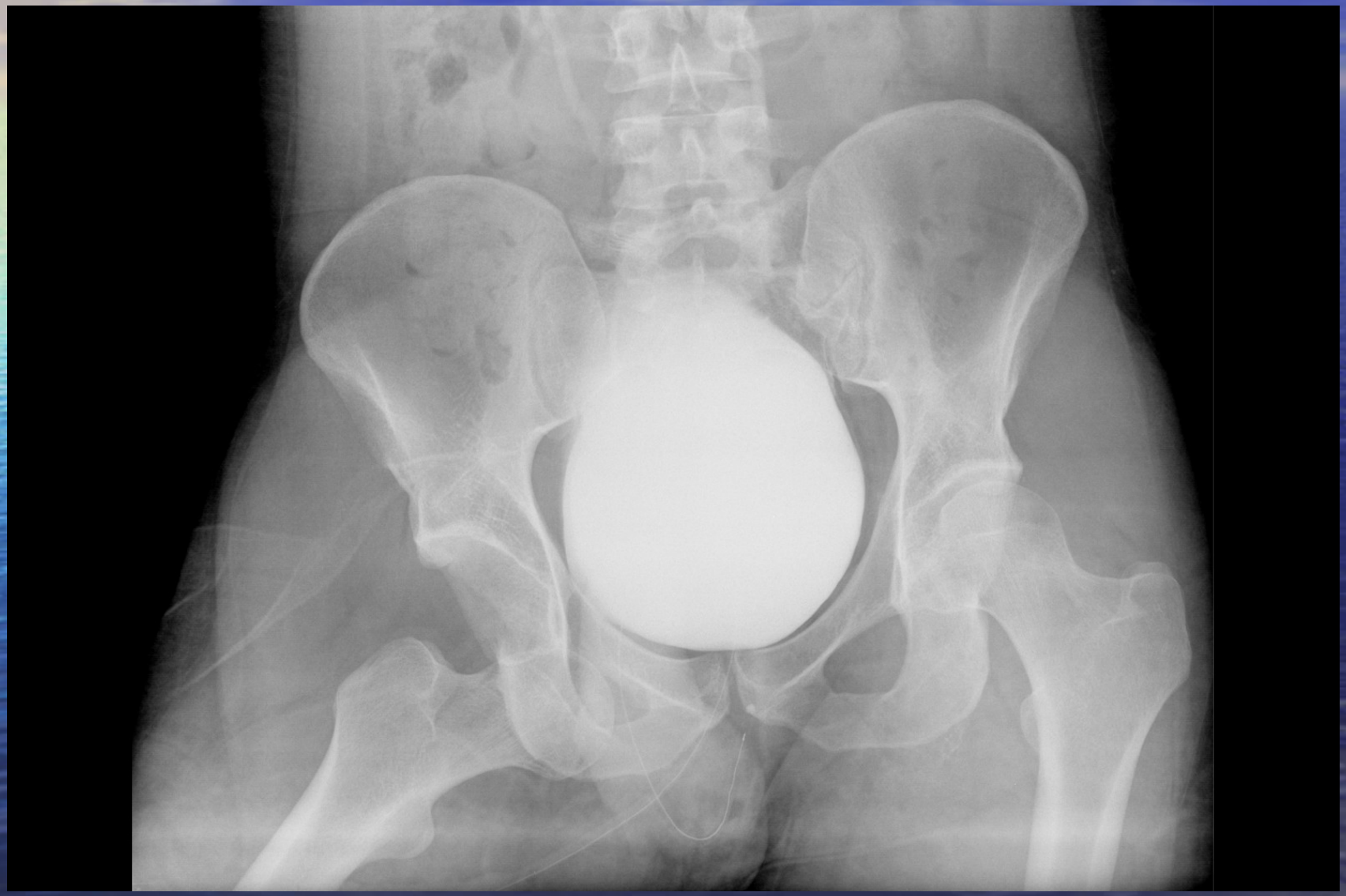

“What you don’t see”

"Hva du ikke ser på et rtg bekken front"

Sacrumfraktur

- Horisontal

Take home message

- Rtg bekken front er en del av traume triage
- Prøv å bringe på det rene hvilke krefter som har virket på bekkenet (MVA / fall ?)
- Sjekk benringene, “alignment” og L5
- Sakrum frakturer vanskelige å se (horisontale)